



## Clinical and economic outcomes assessment with myocardial contrast echocardiography

Leslee J Shaw, Mark J Monaghan and Petros Nihoyannopoulos

*Heart* 1999;82;16-21

---

Updated information and services can be found at:

[http://heart.bmj.com/cgi/content/full/82/suppl\\_3/III16](http://heart.bmj.com/cgi/content/full/82/suppl_3/III16)

---

*These include:*

### Rapid responses

You can respond to this article at:

[http://heart.bmj.com/cgi/eletter-submit/82/suppl\\_3/III16](http://heart.bmj.com/cgi/eletter-submit/82/suppl_3/III16)

### Email alerting service

Receive free email alerts when new articles cite this article - sign up in the box at the top right corner of the article

---

### Topic collections

Articles on similar topics can be found in the following collections

[Other management](#) (291 articles)

[Other Cardiovascular Medicine](#) (2060 articles)

[Other imaging techniques](#) (1504 articles)

---

### Notes

---

To order reprints of this article go to:

<http://www.bmjournals.com/cgi/reprintform>

To subscribe to *Heart* go to:

<http://www.bmjournals.com/subscriptions/>

# Clinical and economic outcomes assessment with myocardial contrast echocardiography

Leslee J Shaw, Mark J Monaghan, Petros Nihoyannopoulos

Routine two dimensional echocardiography is one of the most commonly performed non-invasive tests in the USA and Europe. Key subsets of patients who undergo echocardiography are prone to having a suboptimal image, including obese patients, those with impaired pulmonary function, and elderly patients.<sup>1-3</sup> A number of reviews have estimated that, on average, 10–15% of all routine echocardiograms are suboptimal.<sup>1-4</sup> Ultrasound contrast agents that have been approved for use in Europe and the USA for evaluation of left ventricular opacification and endocardial border delineation include Optison and Levovist.<sup>5</sup> In addition to better delineation of regional myocardial segments, clinical trials are under way to examine the efficacy of these agents for estimating myocardial perfusion.<sup>6, 7</sup> Although providing improved image quality, new advances in the field of ultrasound imaging must be viewed within our current era of limited resources and must be shown to provide added clinical and economic value before they can be assimilated into daily clinical practice.

Over the past two decades, large reductions in mortality and associated cardiovascular complications have been accomplished as a result of new therapeutics and devices in the treatment or prevention of coronary artery disease. New cardiovascular disease tests and treatments have resulted in profound reductions in mortality.<sup>8</sup> In the USA and in Europe, a major factor contributing to the high costs of health care have been new therapeutic and technological advances. It is estimated that one third of the costs of care are attributable to new technology.<sup>9-13</sup>

With the integration and globalisation of world markets, the resulting free market economies increasingly dictate the organisation, financing, and delivery of health care. As

a result of the development of new medical technology and treatments, the costs of health care rise. With higher health care costs, the resulting delivery and financing of health care evolves within a framework of cost constraints, with an emphasis on decreasing resource use and decreasing the selective use of expensive technology. In addition, governments and health care systems are increasingly requiring the establishment of the cost implications of use in relation to any test's added diagnostic value. For example, the National Health Service instituted the National Institute for Clinical Excellence to evaluate new technology and overall quality of care in the UK. In the USA, health care payers, such as Blue Cross and Blue Shield, have set up technology evaluation centres to assess the added clinical and economic value of new treatments and procedures.

There is the potential for new technology to increase the clinical value of the patient's investigations as well increasing costs (fig 1). This paper examines the available clinical and economic benefits of myocardial contrast echocardiography and gives a brief description of the types of economic analyses that can be used.

## Types of economic analyses

### SOCIETAL STANDARDS FOR AN ECONOMIC BENEFIT

The aim of an economic analysis is to understand the cost of alternative health care testing or treatments (for example, the use of digoxin treatment as compared with the use of seat belts or disk brakes on automobiles). Societal standards are then developed into a common metric, called a league table, for the comparison of available tests or treatments.<sup>14-21</sup> Table 1 depicts the different types of economic analyses.

### COST MINIMISATION (SAVINGS) PRINCIPLES

Cost minimisation can be defined as the lowest cost strategy given similar outcomes between the tests being compared.<sup>22-29</sup> In the evaluation of suspected coronary disease, only patients who have evidence of regional dyssynergy (previously undiagnosed without contrast) are referred for further testing, thus controlling costs for all patients and limiting the use of additional testing to fewer patients.<sup>28</sup> Tests that are highly accurate have a lower rate of false positives (that is, decreased cost waste as a result of overuse of cardiac catheterisation or other investigations) and a lower rate of false negative tests (that is, decreased cost waste as a result of a reduction in hospitalisation for unstable angina or myocardial infarction). For contrast echocardiography, a reduction in false

Emory University,  
Atlanta, Georgia, USA  
L J Shaw

King's College  
Hospital, London SE5  
9RS, UK  
M J Monaghan

Cardiology  
Department, Imperial  
College School of  
Medicine and  
Technology,  
Hammersmith  
Hospital, Du Cane  
Road, London  
W12 0NN, UK  
P Nihoyannopoulos

Correspondence to:  
Dr L J Shaw, Emory Center  
for Outcomes Research,  
Room 638, 1518 Clifton Rd  
NE, Atlanta, GA 30322, USA  
email: lshaw@cces.emory.edu

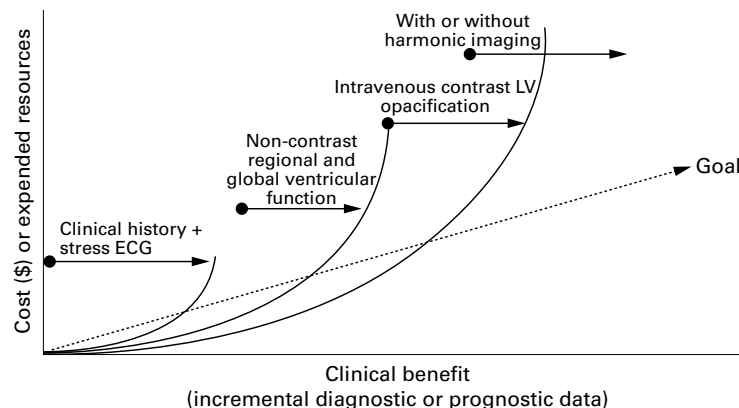


Figure 1 Interaction of cost quality with new advances in echocardiography. ECG, electrocardiography; LV, left ventricular.

Table 1 Types of economic analysis

|   |
|---|
| Cost savings  |
| • Lowest cost strategy with equivalent outcomes   |
| Cost benefit  |
| • Comparison of two strategies—all inputs are converted to a monetary value   |
| • Difference >\$0 indicates an ineffective strategy   |
| Cost effectiveness analysis (CEA)   |
| • Cost for each quality adjusted life year saved or life year saved   |
| Cost utility  |
| Cost/quality adjusted life years  |
| CEA techniques used to compare test modalities  |
| • CEA = incremental cost of one test or test driven strategy <i>v</i> another divided by the incremental benefit of the same test |
| • Relates to the economic resources consumed by the test in relation to the benefits attained by that test                        |
| • Equation  |
| Incremental CE = $\frac{C_{\text{Test \#1}} - C_{\text{Test \#2}}}{O_{\text{Test \#1}} - O_{\text{Test \#2}}}$ (Equation)         |

C, cost of test; O, benefits of test.

positive or negative tests and increased accuracy could result in lower costs of care for at risk patients. In particular, improved visualisation of wall motion, thickness, and/or perfusion could reduce unnecessary cardiac catheterisation or downstream events (table 2).

#### COST EFFECTIVENESS ANALYSIS

Cost effectiveness analysis techniques can be used when comparing varying test modalities—for example, the cost effectiveness of myocardial perfusion tomography compared with myocardial contrast echocardiographic perfusion.<sup>14-21</sup> Cost effectiveness can be defined as the incremental cost of one test or test driven strategy over another, divided by the incremental benefit of the same test or treatment. Such an analysis relates the economic resources consumed by the test in relation to the benefits attained by that test. For a test to be more cost effective, the costs of care need to be decreased and/or the outcome improved. When both cost and outcomes are improved, then the test of choice is termed a dominant strategy. Testing is cost effective in subsets of patient in whom the test is diagnostically and prognostically accurate because cost effectiveness ratios become more favourable.<sup>14-21</sup> For cost effectiveness analysis, cost for each life year or quality adjusted life year saved is frequently used as the measure of comparison; less than US\$50 000/life year saved (in the USA) is the threshold for economic efficiency. Other measures of cost effectiveness might include the cost to identify a cardiac death or myocardial infarction, or the cost to identify pronounced coronary disease. Using a definition of the cost to identify coronary disease, we developed a simulation model comparing the incremental cost of contrast

Table 2 Classification of expected costs by non-invasive test results

| Test result | Negative outcome        | Positive outcome        |
|-------------|-------------------------|-------------------------|
| Negative    | Low cost<br>(true -)    | Cost waste<br>(false +) |
| Positive    | Cost waste<br>(false -) | High cost<br>(true +)   |

True -, post-test resource use is low; true +, post-test resource use is appropriately high, including catheterisation and intervention (as needed); false -, after negative test, patient presents with documented coronary artery disease (such as acute myocardial infarction); false +, after positive test, patient is found to have no coronary artery disease (for example, normal catheterisation).

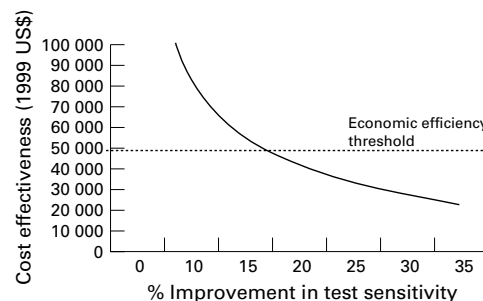


Figure 2 Theoretical relation between the cost effectiveness (cost to identify heart disease) using stress contrast echocardiography and improvement in test sensitivity.

with other diagnostic testing modalities by the per cent improvement in disease detection (that is, sensitivity; fig 2). It is estimated that improvements in test sensitivity beyond 15% could result in a substantial improvement in cost effectiveness.

#### CLINICAL IMPLICATIONS OF MYOCARDIAL CONTRAST ECHOCARDIOGRAPHY USE

Research has shown that myocardial contrast echocardiography provides a clear definition of regional wall motion and thickening as well as enhancing delineation of the left ventricular chamber for patients with technically difficult images at rest and during exercise.<sup>2-7</sup> For patients with a poor acoustic window, reports have noted a 50–90% improvement in added visualised segments.<sup>7 28</sup> The incremental value of contrast echocardiography is approximately 37% additional diagnostic information. In the diagnostic investigation of patients, an improvement in image quality is but one part of an efficient diagnostic strategy of care.

An improved image may also aid in decreasing the time to diagnosis. For contrast echocardiography to be of value, it must also answer the patient's principal diagnostic question (reason for referral). Of patients referred for the evaluation of chest pain, the addition of one dysfunctional myocardial segment might generate additional diagnostic information. The use of a contrast agent might alter laboratory efficiency as well as patient diagnostic efficiency. For contrast echocardiography, potential advantages are enhanced laboratory throughput, as a result of a decrease in time to image difficult patients, and enhanced clinical decision making for echocardiographers, as a result of enhanced visualisation. Although the time required to place an intravenous line need to be taken into account, there will be further improvements in the time to diagnosis when perfusion imaging becomes part of the echocardiographic armamentarium.

Myocardial contrast echocardiography also enhances diagnostic confidence in stress echocardiography imaging, with improvements in image quality in approximately 50% of patients.<sup>2-7 28</sup> From a 203 patient multicentre series, Optison imaging resulted in a higher percentage of studies (74%) being converted to diagnostic echocardiograms compared with the first generation agent, Albutex (26%;  $p < 0.0001$ ), using a blinded core laboratory interpretation.<sup>28</sup> Diagnostic yield may be

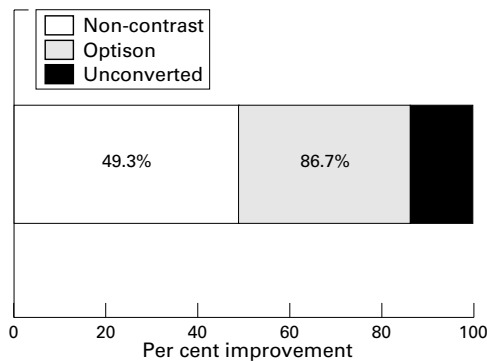


Figure 3 Improvement in diagnostic accuracy in a phase II trial with the use of Optison ( $p < 0.01$ ).

defined as sufficient information to answer the reason for referral. From a phase III trial, the diagnostic yield with Optison was 87%, compared with 49% with unenhanced echocardiography (fig 3;  $p < 0.001$ ). Similar results have been reported with other unapproved agents, revealing a 91–97% visualisation of left ventricular segments with myocardial contrast echocardiography.<sup>6,7</sup> Other agents have revealed modest concordance rates of contrast enhanced wall motion to nuclear perfusion abnormalities (range, 54–61%).<sup>6,7</sup>

Because of the recent approval of myocardial contrast echocardiography agents, few reports have documented the estimation of prognostic outcomes with this technique. In a small study of 50 patients, microvascular integrity was assessed on day 2 postinfarction.<sup>30</sup> Patients with unacceptable peak grey scale ratios ( $\leq 0.46$ ) had a higher rate of cardiac events (defined as death, reinfarction, and admission for heart failure); for a median of 22 months of follow up events were 28% *v* 4% (Cox hazard ratio, 8.5;  $p = 0.05$ ). Furthermore, patients with a risk area of  $> 0.45$  on day 1 and a peak grey scale ratio  $\leq 0.46$  had a relative risk of 10.7-fold. In another recent study of the value of myocardial contrast echocardiography in estimating improvement in regional ventricular function for patients undergoing coronary revascularisation, a surrogate prognostic outcome, myocardial contrast echocardiography had an excellent negative predictive value ( $> 80\%$ ) for estimating attenuated regional function 60 days after surgery.<sup>31</sup> A moderate to strong correlation (0.5) was reported between contrast wall motion scores and nuclear perfusion defect severity ( $p < 0.0001$ ) for the estimation of myocardial viability in 21 patients with chronic coronary disease.<sup>32</sup> Using myocardial contrast echocardiography before and three months after revascularisation, the negative and positive predictive values were 87% and 81%, respectively, for improved regional function recovery (24 patients with acute myocardial infarction).<sup>33</sup>

#### INCREMENTAL VALUE OF HARMONIC IMAGING

Harmonic imaging has also been proposed as a new method to improve detection of echocardiographic abnormalities over fundamental imaging.<sup>2-7,34</sup> The technique has been used to enhance myocardial visualisation. To evaluate the true incremental value of myocardial

contrast echocardiography, it is imperative to discern the amount of independent information defined by harmonic imaging alone. In a recent report by Spencer and colleagues in 20 patients, harmonic images had less clutter and better myocardial blood contrast.<sup>34</sup> Furthermore, individual segments had enhanced visualisation with harmonic imaging in 30–70% of segments in apical four chamber views. During dobutamine stress testing, the overall number of interpretable segments improved by 20% with the use of harmonic imaging. Many segments traditionally difficult to image were improved with harmonic imaging, with more segments being clinically interpretable during stress testing.<sup>34</sup> For those with an initially suboptimal echocardiogram, sufficient diagnostic information to aid in clinical management can still be obtained in 25–30% of patients.<sup>5,32</sup> Furthermore, using preliminary data, it is estimated that harmonic imaging provides a modest improvement in visualisation ( $\sim 20\%$ ), with greater improvements noted with myocardial contrast echocardiography.<sup>5,7,34</sup> Figure 4 depicts an estimation of the added diagnostic value of harmonic imaging, with or without intravenous contrast agents. Although few reports have compared harmonic and contrast imaging in a sufficiently large patient sample,<sup>2-7</sup> it is estimated that the combined use of an intravenous contrast agent with harmonic imaging might provide the greatest amount of added diagnostic information.

#### Cost implications of myocardial contrast echocardiography use

##### CONTRAST ENHANCED REST TWO DIMENSIONAL ECHOCARDIOGRAPHY

Potential cost savings with contrast echocardiography were explored recently.<sup>28</sup> The principle underlying this analysis is that improved technical efficiency with contrast enhancement results in a reduction of downstream resource use. For the patient with a suboptimal echocardiogram who does not receive contrast, the principal diagnostic question may remain and, as such, patient management might be less efficient.

Using this reasoning, improved diagnostic certainty lowers patient care costs and decreases extraneous resource use. In a secondary analysis of 203 patients undergoing

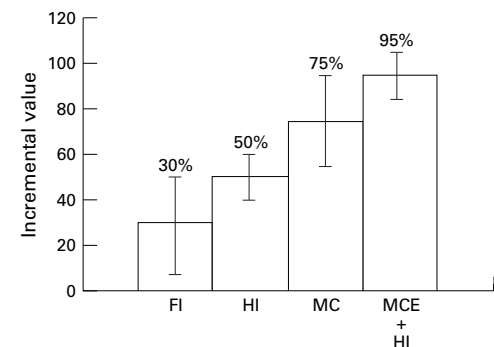


Figure 4 Incremental value of harmonic imaging with and without contrast agent use. FI, fundamental imaging; HI, harmonic imaging; MC(E) myocardial contrast echocardiography.

non-contrast and contrast echocardiography, the results of this analysis revealed that the diagnostic yield was enhanced with the use of intravenous Optison (by approximately 40%) compared with non-contrast echocardiography (fig 3;  $p < 0.001$ ). Because of improved image quality in this difficult to image patient cohort, follow up testing was recommended in 42% of non-contrast echocardiograms and in only 12% of contrast echocardiograms ( $p < 0.001$ ). The resultant costs were 18% lower with the use of a contrast agent ( $p < 0.0001$ ). Use of Optison increased the initial diagnostic cost by US\$110 but resulted in a decrease (17–70%) in confirmatory transoesophageal echocardiography, catheterisation, and nuclear studies. Diagnostic accuracy was improved 2.7-fold for patients with a non-diagnostic echocardiogram receiving contrast, with substantial cost savings of US\$319/patient. Thus, the use of contrast could result in a dominant strategy of improved effectiveness and cost savings.<sup>28</sup> In addition to improved accuracy, a further report suggested that contrast is able to reduce intra-observer and interobserver variability in the evaluation of regional wall motion abnormalities.<sup>35</sup>

#### CONTRAST ENHANCED STRESS TWO DIMENSIONAL ECHOCARDIOGRAPHY

For stress imaging, it is estimated that contrast might enhance accurate diagnosis because of the limited time available for image acquisition and poor image quality at peak stress. With this limited time, echocardiographers often struggle to document the views and anatomic landmarks for test interpretation. As a result of improved endocardial delineation, the use of contrast agents in stress echocardiography might result in an estimated 50% improvement in test quality and improve interobserver variability.<sup>6</sup>

With limited financial resources, we should consider shifting resources to less expensive testing that give a similar diagnostic and prognostic accuracy. For stress echocardiography, recent reports have suggested that its diagnostic accuracy is similar to nuclear myocardial perfusion imaging.<sup>36, 37</sup> The addition of contrast perfusion information in the future might add incremental information for patient management that could help decrease false positive (for example, wall motion abnormality with normal perfusion) and false negative (for example, lack of wall motion abnormality with decreased in myocardial uptake of a contrast agent) test results (table 2). The combination of discerning myocardial perfusion, thickness, and global and regional wall motion could provide a “one stop” test for cardiology at potentially lower test costs. At the Emory Uni-

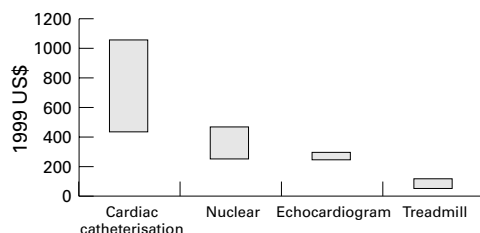


Figure 5 Estimated diagnostic test costs.

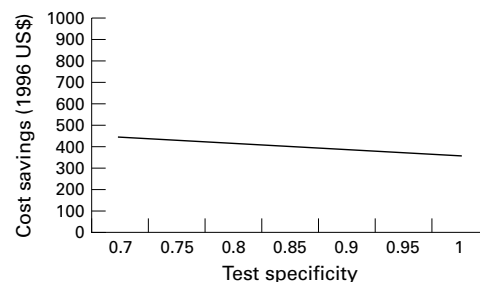


Figure 6 Cost savings of myocardial contrast echocardiography versus SPECT imaging across a range of test specificities.

versity Hospital (Atlanta, Georgia, USA), the average cost of producing one stress echocardiogram is US\$291, compared with US\$469 for gated SPECT imaging (fig 5). Despite the added cost of a contrast agent, stress contrast echocardiography could still provide a 15% cost saving, given similar accuracy and outcome assessment. Although the absolute values may differ, the relative savings should still apply in different world wide health systems.

An analysis of the cost effectiveness of stress contrast echocardiography compared with nuclear perfusion imaging was reported recently.<sup>38, 39</sup> For diagnostic cardiology, short term costs are affected dramatically by the rate of false positive non-invasive test results. Thus, this analysis compared the added value of contrast imaging in affecting changes in false positive test results with the addition of contrast perfusion information. In a dataset of 24 patients (average age 64 years, 80% typical angina history), the sensitivity and specificity of contrast echocardiography using SPECT ischaemia as the gold standard were 86% and 100%, respectively.<sup>37</sup> Average cost savings were US\$348–450 with contrast echocardiography and there was a minimum 10% improvement in false positive rates (fig 6).<sup>24</sup>

Recent observational series from Europe and the USA have noted that cardiac imaging driven diagnostic strategies might result in fewer expended resources (expensive coronary revascularisation procedures), although achieving similar outcomes to the more aggressive, diagnostic catheterisation approaches.<sup>22, 29</sup> The “economics of myocardial perfusion imaging study” enrolled 396 patients from eight European hospitals and compared the costs and clinical outcomes for patients who proceed to a variety of diagnostic strategies, including direct catheterisation, nuclear imaging, and selective catheterisation.<sup>29</sup> Total two year costs were £6047 for direct catheterisation compared with £4854 for nuclear driven patient management.<sup>29</sup> In the “economics of non-invasive diagnosis study”, total costs were 30–41% lower for nuclear imaging compared with cardiac catheterisation for stable patients with chest pain.<sup>22</sup> Additional cost savings would be expected using lower cost echocardiography, with and without contrast agents.

#### CURRENT LIMITATIONS OF AVAILABLE DATA

Because this technique is so new, it will be essential not only to assess the efficacy of current contrast agents (either approved or in

development), but also their effectiveness in improving patient management. Despite the potential cost savings that could be accrued in shifting patients from other modalities to contrast echocardiography, it is crucial that a similar level of diagnostic and prognostic accuracy be achieved, so that downstream care is unaffected. Currently, the body of prognostic evidence with nuclear imaging is more widely established in diverse patient samples than with echocardiography, although there are a number of recent reports detailing clinical outcomes.<sup>40-42</sup> Using evidence based practice, data on contrast echocardiography will have to establish its incremental value over and above other techniques. However, preliminary results from small patient samples, derived predominantly from preapproval clinical trials, reveals positive evidence that the use of a contrast agent might produce real improvements in clinical decision making.

### Summary

Despite the newness of available myocardial contrast echocardiographic agents, there is a growing body of evidence that demonstrates their clinical and economic value. In general, an overall improvement in image quality is seen with the use of intravenous contrast agents in patients with an initially poor acoustic window. The added value of contrast might be especially important for patients undergoing stress echocardiography. Given a similar diagnostic accuracy, shifting of resources from nuclear to stress contrast echocardiographic imaging could provide tremendous cost savings for the limited financial resources of any European country or North American state.

Grant support has been provided to the authors for research detailed in this review paper including institutional support from Bertex Laboratories and Molecular Biosystems. No financial support was received for the preparation of this document.

- 1 Hsieh A, Jollis JG, Kesler KL. Prognostic value of transthoracic echo in the Duke cardiovascular disease database [abstract]. *Circulation* 1996;94:1-27.
- 2 Kaul S. Myocardial contrast echocardiography: 15 years of research and development. *Circulation* 1997;96:3745-60.
- 3 Feinstein SB, Becher H, Macioch JE, et al. Rush-Presbyterian-St Luke's clinical use of contrast echocardiography. *A continuing education atlas*. Philadelphia: American Journal of Cardiology, 1998:1-48.
- 4 Kaul S. Myocardial contrast echocardiography. *Curr Probl Cardiol* 1997;22:549-635.
- 5 Cohen JL, Cheirif J, Segar DS, et al. Improved left ventricular endocardial border delineation and opacification with OPTISON (FS069), a new echocardiographic contrast agent. Results of a phase III multicenter trial. *J Am Coll Cardiol* 1998;32:746-52.
- 6 Ikonomidis I, Holmes E, Narbuvoold H, et al. Assessment of left ventricular wall motion and delineation of the endocardial border after intravenous injection of Infuson during dobutamine stress echocardiography. *Coron Artery Dis* 1998;9:567-76.
- 7 Marwick TH, Brunken R, Meland N, et al. Accuracy and feasibility of contrast echocardiography for detection of perfusion defects in routine practice: comparison with wall motion and technetium-99m sestamibi single-photon emission computed tomography. The Nycomed NC100100 investigators. *J Am Coll Cardiol* 1998;32:1260-9.
- 8 Fuster V. Epidemic of cardiovascular disease and stroke. *Circulation* 1999;99:1132-7.
- 9 Levit KR, Lazensby HC, Braden BR. National health expenditures. *Health Aff (Millwood)* 1996;17:35-51.
- 10 Burner ST, Waldo DR, McKusick DR. National health care expenditures. *Health Care Financing Review* 1996;14:1-30.
- 11 <http://www.amhrt.org/stats/1997>.
- 12 Ginzberg E. *Health services research*. Cambridge, MA: Harvard University Press, 1991.
- 13 Fuchs U. *The future of health policy*. Cambridge, MA: Harvard University Press, 1993.
- 14 Drummond MF, Jefferson TO. Guidelines for authors and peer reviewers of economic submissions to the BMJ. The BMJ economic evaluation working party. *BMJ* 1996;313:275-83.
- 15 Finkler S. *Cost accounting for health care organizations: concepts and applications*. Gaithersburg, MD: Aspen Publishers, 1994.
- 16 Laupacis A, Feeny D, Detsky AS, et al. How attractive does a new technology have to be to warrant adoption and utilization? Tentative guidelines for using clinical and economic evaluations. *Can Med Assoc J* 1992;146:473-81.
- 17 Weinstein MC, Stason WB. Cost-effectiveness of coronary artery bypass surgery. *Circulation* 1982;66:III56-66.
- 18 Mark D. *Medical economics and health policy issues for interventional cardiology*. 2nd ed. Textbook of interventional cardiology. Philadelphia, PA: WB Saunders, 1993.
- 19 Weintraub WS, Mauldin PD, Becker E, et al. A comparison of the costs of and quality of life after coronary angioplasty or coronary surgery for multivessel coronary artery disease. Results from the Emory angioplasty versus surgery trial (EAST). *Circulation* 1995;92:2831-40.
- 20 Goldman L, Garber AM, Grover SA, et al. 27th Bethesda conference: matching the intensity of risk factor management with the hazard for coronary disease events. Task force 6. Cost effectiveness of assessment and management of risk factors. *J Am Coll Cardiol* 1996;27:1020-30.
- 21 Shaw LJ, Eisenstein EL, Hachamovitch R, et al. A primer of biostatistic and economic methods for diagnostic and prognostic modeling in nuclear cardiology: part II. *J Nucl Cardiol* 1997;4:52-60.
- 22 Shaw L, Hachamovitch R, Berman D, et al. The economic consequences of available diagnostic and prognostic strategies for the evaluation of stable angina patients: an observational assessment of the value of preatherization ischemia. *J Am Coll Cardiol* 1999;33:661-9.
- 23 Marwick TH, Anderson T, Williams MJ, et al. Exercise echocardiography is an accurate and cost-efficient technique for detection of coronary artery disease in women. *J Am Coll Cardiol* 1995;26:335-41.
- 24 Shaw LJ, Dittrich HC, West H, et al. Cost effectiveness of myocardial contrast echocardiography as compared to nuclear perfusion imaging in the diagnosis of coronary disease. 9th annual scientific sessions of the American Society of Echocardiography, San Francisco, CA, June 10-13, 1998 [abstract]. *J Am Soc Echocardiogr* 1998;11:512.
- 25 Shaw L, Hachamovitch R, Eisenstein E, et al. Cost implications for implementing a selective preoperative risk screening approach for peripheral vascular surgery patients. *American Journal of Managed Care* 1997;3:1817-27.
- 26 Rubin DN, Ballal RS, Marwick TH. Outcomes and cost implications of a clinical-based algorithm to guide the discriminate use of stress imaging before noncardiac surgery. *Am Heart J* 1997;134:83-92.
- 27 Redberg RF. Diagnostic testing for coronary artery disease in women and gender differences in referral for revascularization. *Cardiol Clin* 1998;16:67-77.
- 28 Shaw LJ, Gillam L, Feinstein S, et al. Technology assessment in the managed care era: use of an intravenous contrast agent (FS069-Optison) to enhance cardiac diagnostic testing. *Am J Managed Care* 1998;4:SP169-76.
- 29 Underwood SR, Godman B, Salyani S, et al. Economics of myocardial perfusion imaging in Europe—the EMPIRE study. *Eur Heart J* 1999;20:157-66.
- 30 Sakuma T, Hayashi Y, Sumii K, et al. Prediction of short- and intermediate-term prognoses of patients with acute myocardial infarction using myocardial contrast echocardiography on day after recanalization. *J Am Coll Cardiol* 1998;32:890-7.
- 31 Meza MF, Ramee S, Collins T, et al. Knowledge of perfusion and contractile reserve improves the predictive value of recovery of regional myocardial function post-revascularization: a study using the combination of myocardial contrast echocardiography and dobutamine echocardiography. *Circulation* 1997;96:3459-65.
- 32 Vernon S, Kaul S, Powers ER, et al. Myocardial viability in patients with chronic coronary artery disease and previous myocardial infarction: comparison of myocardial contrast echocardiography and myocardial perfusion scintigraphy. *Am Heart J* 1997;134:835-40.
- 33 Agati L, Voci P, Autore C, et al. Combined use of dobutamine echocardiography and myocardial contrast echocardiography in predicting regional dysfunction recovery after coronary revascularization in patients with recent myocardial infarction. *Eur Heart J* 1997;18:771-9.
- 34 Spencer KT, Bednarz J, Raftar PG, et al. Use of harmonic imaging without echocardiographic contrast to improve two-dimensional image quality. *Am J Cardiol* 1998;82:794-9.
- 35 Crouse LJ, Cheirif J, Hanly DE, et al. Opacification and border delineation improvement in patients with suboptimal endocardial border definition in routine echocardiography: results of the phase III Alburnex multicenter trial. *J Am Coll Cardiol* 1993;22:1494-500.
- 36 Kelsey A, Shaw L, Ryan T. Fifteen years of exercise echocardiography: a meta-analysis. 70th scientific sessions of the American Heart Association, Orlando, FL [abstract]. *Circulation* 1997;96:1-276.
- 37 Fleischmann KE, Hunink MG, Kuntz KM, et al. Exercise echocardiography or exercise SPECT imaging? A meta-analysis of diagnostic test performance. *JAMA* 1998;280:913-20.
- 38 Shaw L, Hachamovitch R, Marwick T, et al. Cost effectiveness analysis of stress myocardial perfusion imaging in stable angina patients: influence of age and pretest risk of coronary disease. 46th annual scientific sessions for the American College of Cardiology 1997, Anaheim, CA [abstract]. *J Am Coll Cardiol* 1997;29:137A.

- 39 Shaw LJ, Ryan T, Cohen JL, *et al*. Estimation of myocardial perfusion with Optison contrast echocardiography. 71st annual scientific sessions of the American Heart Association, Dallas, TX [abstract]. *Circulation* 1998;17:I-214.
- 40 Poldemans D, Fioretti PM, Boersma E, *et al*. Long-term prognostic value of dobutamine-atropine stress echocardiography in 1737 patients with known or suspected coronary artery disease. *Circulation* 1999;97:1474–80.
- 41 Chuah SC, Pellikka PA, Roger VL, *et al*. Role of dobutamine stress echocardiography in predicting outcome in 860 patients with known or suspected coronary artery disease. *Circulation* 1998;97:1474–80.
- 42 McCully RB, Roger VL, Mahoney DW, *et al*. Outcome after normal exercise echocardiography and predictors of subsequent cardiac events: follow-up of 1325 patients. *J Am Coll Cardiol* 1998;31:144–9.